

A complex variation of the vertebrobasilar system

Eray Tuccar (1)
Fatih Yazar (2)
Yalcin Kirici (2)
Hasan Ozan (2)

(1) Department of Anatomy, Ankara University,
Faculty of Medicine, 06100, Sıhhiye, Ankara, Turkey
(2) Department of Anatomy, Gulhane Military
Medical Academy, Faculty of Medicine, 06018, Etlik,
Ankara, Turkey

Correspondence Address

Eray Tuccar, M.D., Ph.D., Assistant Professor.
Department of Anatomy,
Ankara University, Faculty of Medicine,
06100, Sıhhiye, Ankara, Turkey
Tel: 90 (312) 310 30 10/241
Fax: 90 (312) 310 50 01
e-mail: eraytuccar@yahoo.com

Received 19 July 2002; accepted 25 September 2002

Abstract

In the dissection of the posterior fossa of a 62-year-old man was found a complex variation concerning the vertebral arteries and their branches. What we encountered was a very thin intracisternal part of the vertebral artery unilaterally and a rare unilateral origin of the anterior spinal artery. This combined anomaly is important both in diagnosing these mentioned arteries and during surgical procedures related to the vascular structures of the cerebellum and the brain stem.

Key words: vertebral artery, basilar artery, anomaly, variation

Introduction

The intracranial portion of the vertebral artery begins where the artery pierces the dura mater. The right and left vertebral arteries normally join with each other forming the basilar artery at the level of the pontomedullary junction. The intracranial vertebral artery gives off medial and lateral branches. Two major medial branches are known: the anterior spinal artery and the branches of the foramen magnum. There are many studies about the microsurgical anatomy of these arteries but a photographic demonstration of such an arterial variation is not shown. Therefore this case of rare feature is demonstrated and discussed.

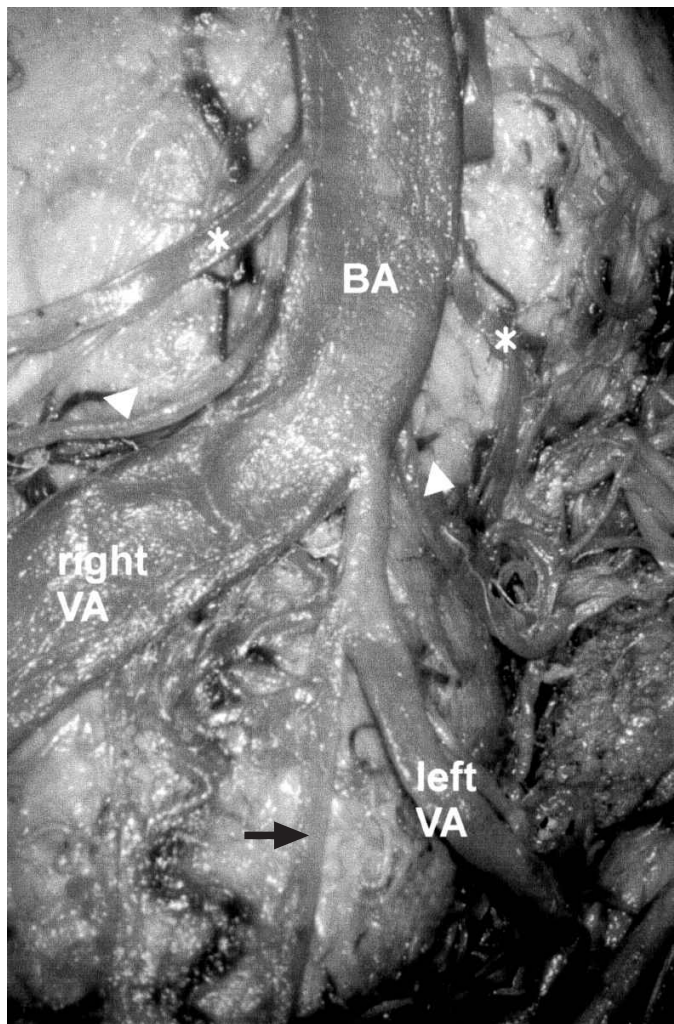
Case Report

In the dissection of the posterior fossa of a 62-year-old male cadaver embalmed with formalin was found a complex variation concerning the vertebral arteries and their branches. After removing the calvaria and the cerebrum, the artery and its branches were visualised with the brain stem from the anterior approach. Using a surgical microscope, the microdissections were completed and the outer diameters and the distances between the structures were measured. In this case, the left vertebral artery had an intracisternal width of 1.1 mm. Inside the subarachnoid space; the artery ran anteriorly towards the two root fibre bundles of the hypoglossal nerve. The right vertebral artery was unusually wide (5.5 mm). The transverse foramina of the axis bone on both sides were normal particularly in diameters. The right and left vertebral arteries joined each other with a 45° angle, forming the basilar artery at the level of the pontomedullary junction which is normal. The basilar artery

looked like the extension of the right vertebral artery, where the left vertebral artery was a smaller vessel unifying this trunk from the lateral side. The larger right vertebral artery and the basilar arteries together made a curve to the left (Fig. 1) where the basilar artery gave rise to the anterior inferior cerebellar artery and the labyrinthine artery. Anterior spinal artery was formed unilaterally from the undersized left vertebral artery. Anterior spinal artery proceed from the narrower side (left) of the vertebral artery 4 mm away from the vertebrobasilar junction. The artery had a descending course, with distribution into the ventral face of the medulla oblongata and the first cervical segments of the medulla spinalis.

Discussion

Akar et al. [1] studied the intracranial portion of the vertebral artery and its branches and they evaluated the course of vessels and their dimensions, as well as the relations between each of them. The unilateral narrowing of the vertebral artery is not mentioned in their studies about the microsurgical anatomy of the intracranial part of the vertebral arteries. Grand et al. [2] made a study about the microvascular anatomy of brains to develop anatomical guidelines for aneurism surgery in the region of the vertebrobasilar junction. They noticed that the morphologies of the main arteries were characteristically variable whereas the perforators were unvarying, particularly in terms of their numbers and points of penetration into the brain substance. Likewise, the unilateral narrowing of the vertebral artery was not mentioned in this study. Lang [3] reported a case about a rare variation of the vertebral arteries. In this case the vertebral artery of the right side had an



intracisternal width of 0.9 mm. The left vertebral artery was unusually wide (5.5 mm) and it had a bend to the left side. Ebraheim et al. [4] reported that the variation of the foramen size between sexes was more significant than that between sides as we did not find a difference between the both sides of the transverse foramina of the axis. Govsa et al. [5] in their investigation to extend the knowledge of the origin of the anterior spinal artery examined 80 brains of human cadavers and found that unilateral origin of the anterior spinal artery was found in 9 specimens (11.3 %). In a similar study Rodriguez-Baeza et al. [6] carried out their study using 31 human cadavers and the unilateral origin was 9.7 %. Microanatomical and flowmetric studies are clearly needed to ascertain whether and how maldevelopmental anomalies in the VA course modify its hemodynamics. In this respect, one must keep in mind the natural development of total cerebral blood flow volume [7]. This combined anomaly is important in diagnosing the artery and during surgical procedures related to the vascular structures of the cerebellum and the brain stem. All of these should be kept in mind by the surgeon approaching the deep cervical and craniospinal regions as well as by the interventional radiologist.

Figure 1 Right VA: right vertebral artery, left VA: left vertebral artery, BA:basilar artery, arrow heads:anterior inferior cerebellar artery, asterisks:labyrinthine artery, arrow: anterior spinal artery.

References

- [1] Akar ZC, Dujovny M, Slavin KV, Gomez-Tortosa E, et al. Microsurgical anatomy of the intracranial part of the vertebral artery. *Neurol. Res.* 1994 (16) 171-180.
- [2] Grand W, Budny JL, Gibbons KJ, Sternau LL, et al. Microvascular surgical anatomy of the vertebrobasilar junction. *Neurosurgery* 1997 (40) 1219-1223.
- [3] Lang J. About a very rare variation of the course and width of the vertebral arteries and the hypoglossal nerve. *Acta Neurochir.* 1990 (106) 73-77.
- [4] Ebraheim NA, Xu R, Lin D, Haman S, et al. Quantitative anatomy of the transverse foramen and pedicle of the axis. *J. Spinal Disord.* 1998 (11) 521-525.
- [5] Govsa F, Aktan ZA, Arisoy Y, Varol T, et al. Origin of the anterior spinal artery. *Surg. Radiol. Anat.* 1996 (18)189-193.
- [6] Rodriguez-Baeza A, Muset-Lara A, Rodriguez-Pazos M, Domenech-Mateu JM. Anterior spinal arteries. Origin and distribution in man. *Acta Anat.* 1989 (136) 217-221.
- [7] Giuffrè R, Sherkat S. Maldevelopmental pathology of the vertebral artery in infancy and childhood *Childs Nerv. Syst.* 2000 (16) 627-632.

————— N —————